

Polarized light camera to guide surgical excision of skin cancers

Steven L. Jacques^{a,b,*}, Ravikant Samatham^a, Scott Isenhath^b, Ken Lee^b

^aBiomedical Engineering, Oregon Health & Science Univ., 3303 SW Bond St., Portland, OR, 97239

^bDermatology, Oregon Health & Science University, 3303 SW Bond St., Portland, OR, USA 97239

ABSTRACT

A polarized light camera (polCAM) is being used to guide surgical excision of skin cancers. Preliminary results of a clinical pilot study are presented. The polCAM uses linearly polarized light and acquires parallel- and cross-polarized images, then the difference image (par - cross) subtracts the background diffusely scattered light and yields an image that unveils the fabric of the skin. Cancer disrupts the complex pattern of this fabric, revealing the cancer margin.

Keywords: polarized light camera, skin cancer, reflectance, diagnostic imaging

1. INTRODUCTION

A polarized light camera (polCAM) is able to create images based on the superficially scattered photons from subsurface layers of the skin [1-3]. The images enable the doctor to visualize the “fabric” of the skin, which is a complex pattern. Skin cancer disrupts this fabric pattern. The doctor’s eye can detect this flaw in the skin fabric and visualize the margins of skin. This pilot clinical study tests the ability of the polCAM to identify the margins of skin cancer and to guide surgical excision.

2. METHODOLOGY

2.1 Basics of the polCAM

The camera operates by illuminating the skin with linearly polarized light obliquely at an angle of 30 degrees off the normal, such that the surface glare is reflected away from the camera. The camera views the skin from above, along the axis normal to the tissue. The field of view is 7x5 mm², as a 640x480-pixel 12-bit image. A set of these pictures can be assembled into a mosaic picture that has a larger field of view.

The camera is a monochrome CCD camera (Flea, Point Grey, Vancouver, BC) that feeds images via Firewire to a PC computer, operating Labview software which controls image acquisition at 30 fps. The system controls a liquid crystal Faraday rotator, followed by a linear polarizer, and this combination allows electronic switching to collect either linearly polarized light parallel (PAR) to the illumination light or perpendicular (PER) to the illumination light. The system acquires 10 images of each type of polarization and averages, to yield two averaged images, PAR and PER. The difference image is calculated.

$$\Delta POL = PAR - PER \quad (1)$$

The images PER and ΔPOL are saved, which are essentially a normal diffuse light image (PER) and a polarized light image (ΔPOL).

2.2 Clinical protocol

Patients scheduled for Mohs surgery that presented a squamous cell carcinoma (SCC) or basal cell carcinoma (BCC) were recruited into the study.

Step 1: Mark grid on skin site A flexible plastic sheet with a grid of holes was placed on the skin site, and a black marking pen was placed in each hole to mark the skin with a grid of dots.

Step 2: Clinical margins The doctor observed the skin site and visualized the cancer margins, then marked this margin with a dashed line.

Step 3: Preliminary image A clinical image of the skin site was taken with a standard hand-held digital camera, with a linear polarizer placed over the flash lamp and a cross-polarized placed in front of the lens. This avoided glare from the skin surface. The image showed the lesion, the grid of dots, and the dashed line of the clinical margin.

Step 4: Mosaic image The hand-held polCAM was manually placed on each square marked by 4 dots within the grid, and an image set (PAR, Δ POL) acquired. Typically the grid allowed for a 6x6 or 36 images. Subsequent analysis co-registered the images based on the common dots in each image, to yield mosaic PER and Δ POL images.

Step 5: Surgical excision The excision was based on the clinical margins.

Step 6: Image of excised site A 2nd clinical image of the skin site was taken, which documented the 1st excision.

Step 7: Pathology examination The dermatopathologist evaluated the excised tissue and returned a diagram showing where the skin cancer margin still remained, requiring a second excision.

Step 8 (as needed): 2nd excision As needed, a 2nd (or more) excision was made. A clinical with the digital camera image was acquired after each excision.

2.3 Analysis

The mosaic image was prepared using either PhotoshopTM or a MATLABTM program to co-register the images. Work on automating this step is on-going.

The mosaic image and the clinical digital images were co-registered on the basis of the black dots, using MATLABTM.

3. RESULTS

The pilot clinical trial is on-going, and the results are not yet ready for report. However, in this report we show some typical images to illustrate the clinical protocol

Figure 1 shows the placement of the grid of dots on a skin site with a BCC. Figure 2 shows close up view of th is grid.

Figure 3 shows the mosaic Δ POL image, superimposed on the digital image. The PER image (Fig. 3A) shows little contrast. The Δ POL image (Fig. 3B) shows the “fabric pattern” of the skin, which is a stippled appearance. The BCC has homogenized the fabric pattern, such that the cancer margins can be discerned.

Figure 4 shows the cancer margin as a blue line superimposed on the Δ POL image of Fig. 4.

Figure 5 shows the excision, with the Δ POL-based cancer margin drawn as a blue line.

In some cases, the Δ POL image could identify a margin that was outside the clinical margin that was excised (not shown here). The subsequent pathologic examination found the unexcised margin, agreeing with the Δ POL image, and a 2nd excision was required. The Δ POL image appears to be able to discern the cancer margin and guide surgery. A final judgement awaits the outcome of the study.

4. CONCLUSIONS

The polCAM is able to enhance the fabric pattern of skin for visualization by the doctor. Skin cancer disrupts this fabric pattern, usually by a homogenization of the pattern, which enables the doctor to visualize the cancer margins.

In this on-going pilot study during routine Mohs surgery of SCC and BCC lesions, the ability of the polCAM to visualize the true cancer margins are compared against (1) the clinical margins seen by the doctor’s eye, and (2) the margins identified by the pathologist’s evaluation of the excised skin samples.

REFERENCES

1. S. L. Jacques, J. Roman, K. Lee: "Imaging superficial tissues with polarized light," *Lasers Surg. Med.* 26, 119-129 (2000).
2. Jacques SL, JC Ramella-Roman, K Lee. "Imaging skin pathology with polarized light," *J Biomed Opt.* 7,329-340 (2002).
3. JC Ramella-Roman, K Lee, SA Prahl, SL Jacques, "Design, testing, and clinical studies of a handheld polarized light camera," *J Biomed Optics* 9(6), 1305-1310 (2004).

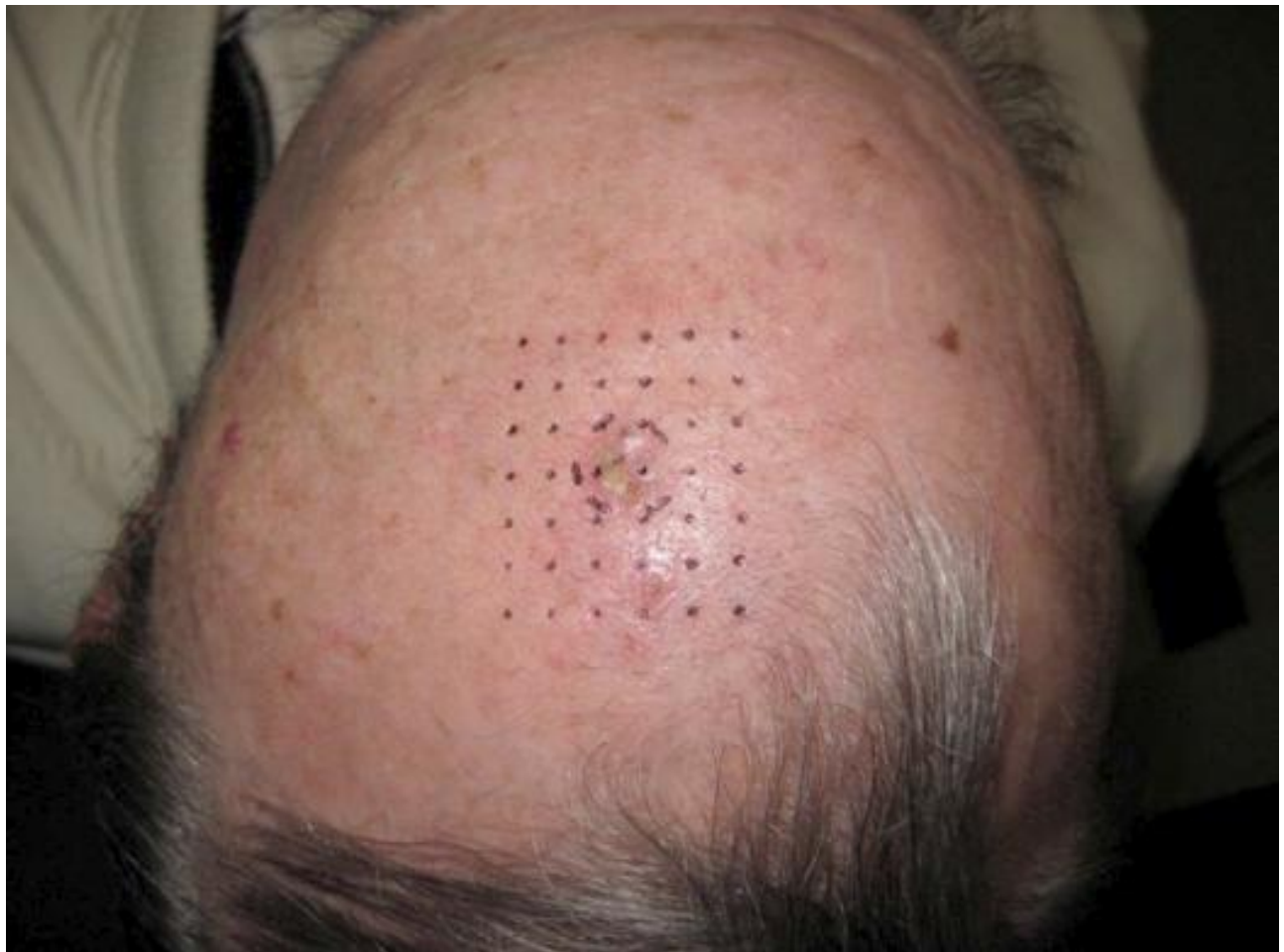

Fig. 1.: The skin site with grid marked by dots, and central BCC.

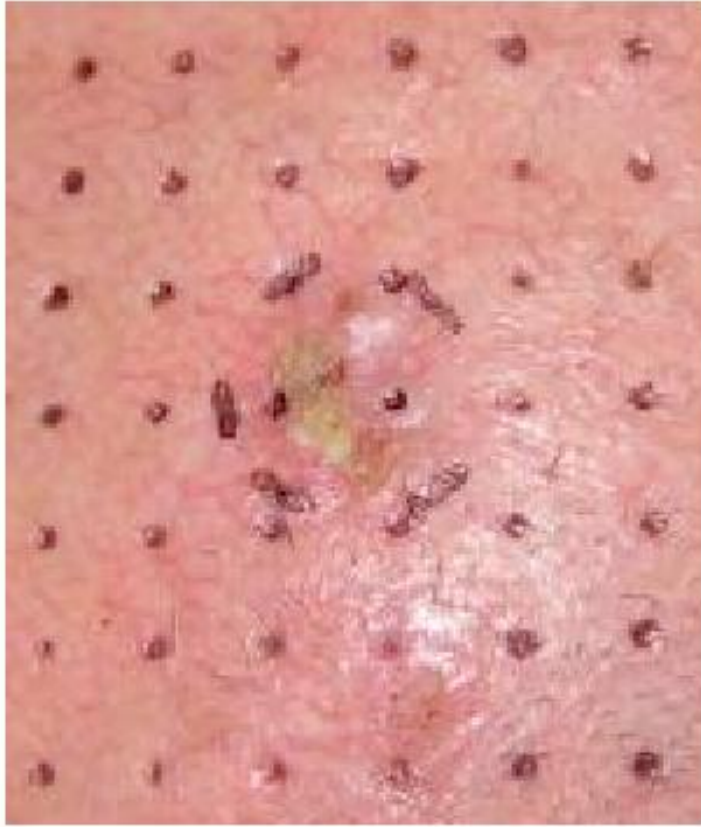

Fig. 2. Close up of preliminary clinical image of BCC, with dots from grid and dashed lines by doctor showing clinical margin.

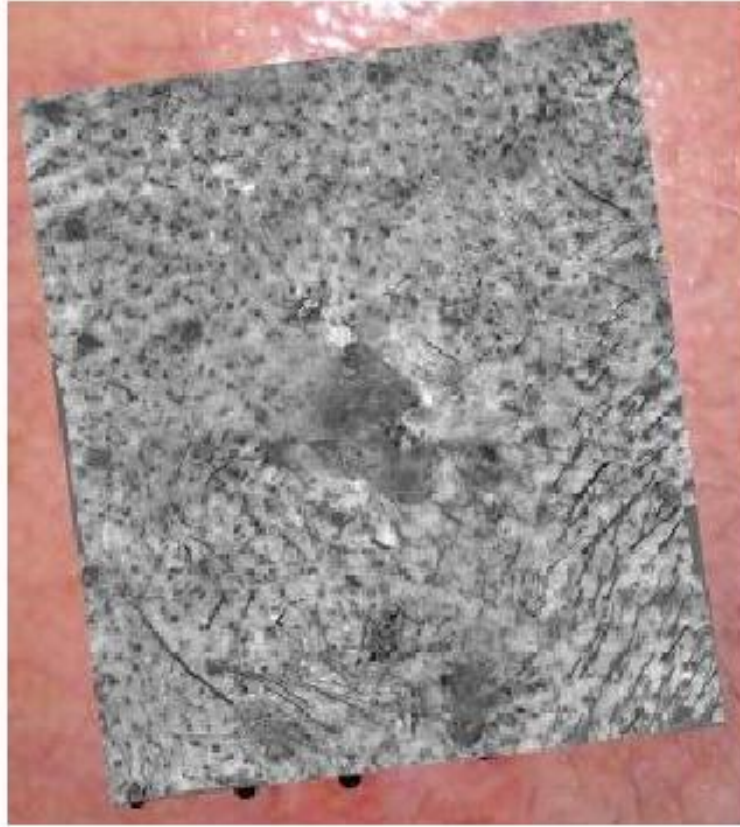


Fig. 3. The polarized light image (Δ POL) superimposed onto the digital camera image of the skin site.

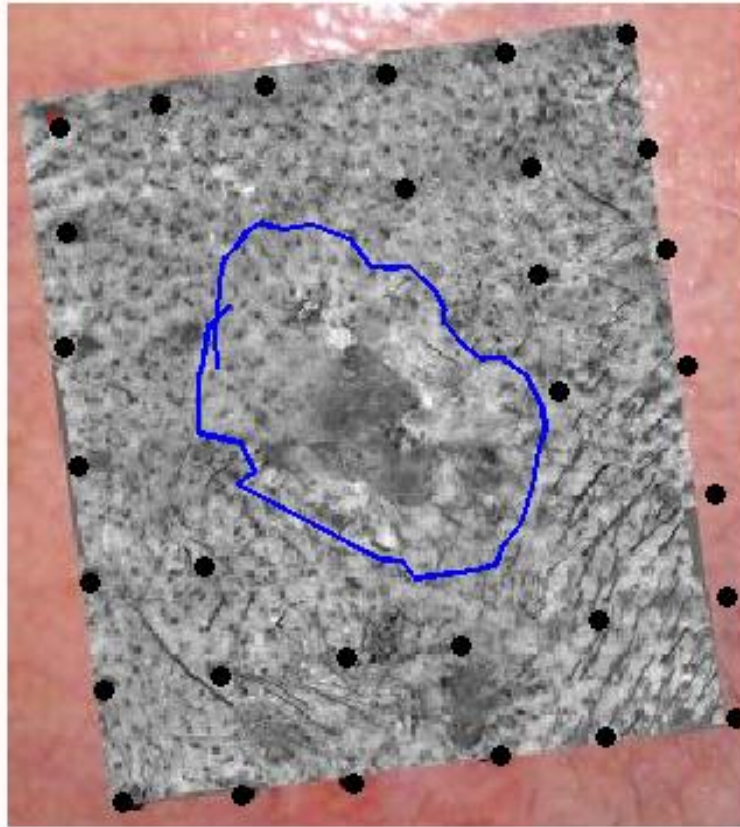


Fig. 4. Same as Fig. 3, but with dots redrawn by computer. The blue line is the cancer margin determined by observing this Δ POL image. The dots have been redrawn by the computer to improve legibility in this report.

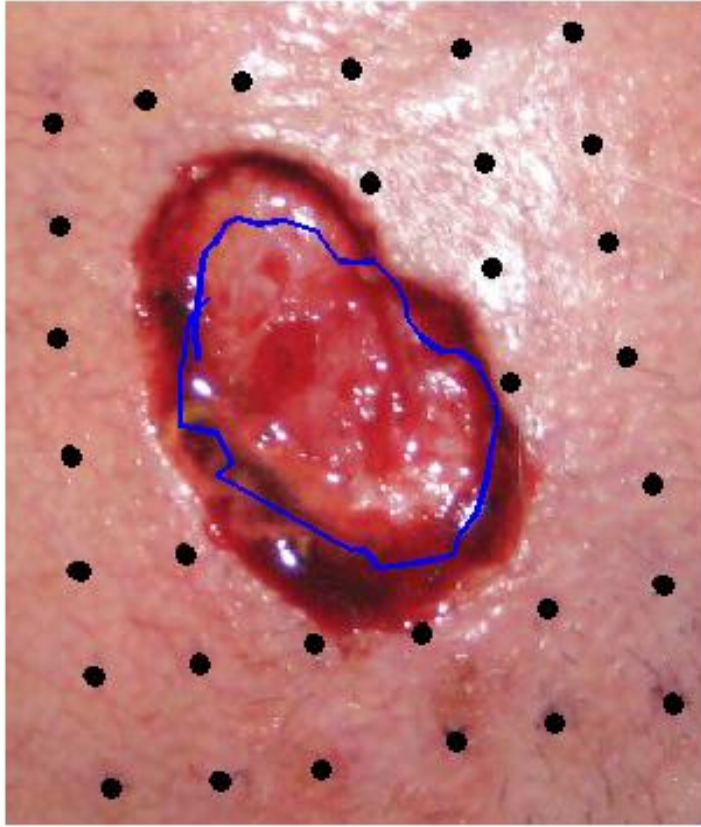

Fig. 5. The excised skin site, with the blue line of the cancer margin from Fig. 4 based on the Δ POL image. The dots have been redrawn by the computer to improve legibility in this report.